

wewnętrzny i poufny dla członków FAAAAAR, a moja wiedza pozostaje powierzchowna i ograniczona.

Wszyscy natomiast wiemy, jak jest w Polsce — zasadniczo odwrotnie. W kwestii anestezjologii i intensywnej terapii istnieje kilka ośrodków decyzyjnych, a każdy z nich ma raczej inne cele statutowe. Od czasu do czasu PTAiT, Związek Zawodowy Anestezjologów i konsultant krajowy jednoczą jednak swe wysiłki — ostatnio w sprawie nowej specjalizacji z intensywnej terapii. Jaki będzie efekt ich działania tej ważnej sprawie, zobaczymy.

Może warto zastanowić się i podyskutować nad niektórymi rozwiązaniami, które dobrze funkcjonują

w innych krajach, między innymi w Argentynie, zabezpieczając od lat status materialny anestezjologów w warunkach prawie permanentnego kryzysu ekonomicznego kraju? „Socjalizm medyczny” króluje w ustach polityków (populizm) i wymaganiach pacjentów (roszczeniowość), lecz na rynku usług medycznych w kraju panuje dziś dziki kapitalizm.

Adres do korespondencji:

dr n. med. Wojciech Pietrzyk
Szpital Kielecki św. Aleksandra
ul. Kościuszki 25, 25–316 Kielce
e-mail: dr.pietrzyk.w@gmail.com

Anestezjologia Intensywna Terapia
2016, tom 48, numer 1, 70–74
ISSN 0209–1712
www.ait.viamedica.pl

Snaring swans: intraoperative knotting of pulmonary artery catheters

Lukasz Starzyk¹, Eric Yao², Graham Roche-Nagel³,
Marcin Wasowicz²

¹Department of Anaesthesia and Pain Medicine, University Hospital Bern, Bern, Switzerland

²Department of Anaesthesia and Pain Management, Toronto General Hospital, University Health Network, Toronto, Canada

³Division of Vascular Surgery, Toronto General Hospital, University Health Network, Toronto, Canada

Key words: knot, Swan-Ganz catheter, percutaneous removal

First introduced in 1970 by HJ Swan and W Ganz, the pulmonary artery catheter (PAC) is an important invasive diagnostic and hemodynamic monitoring tool widely used for patients in cardiac and transplant anaesthesia, or for unstable patients in the intensive care unit. Rare acute complications such as catheter knotting, arterial perforation, thrombosis and arrhythmias are well-documented, with the lattermost being the most prevalent of complications [1]. This letter focuses on PAC knotting, which has an estimated incidence of 0.03% of all PAC insertions [2]. We present a case involving a knotted and entrapped PAC during open heart surgery and describe the management of this complication. This report also reviews the current methodology for the removal of a knotted PAC, both invasive and non-invasive.

A 32 year-old male (who consented to the writing of this report) was admitted to our centre with a newly diagnosed

congenital partial atrioventricular septal defect (AVSD) and no known other history of previous cardiovascular disease. The patient developed late symptoms of congenital heart disease in the form of syncope episodes. On a preoperative transthoracic echocardiogram (TTE), he was found to have a primum atrial septal defect combined with moderate to severe left AV valve regurgitation and moderate right AV valve regurgitation. Right ventricular enlargement with preserved systolic function, as well as normal left ventricular function were noted. The patient's only comorbidity included mild gastroesophageal reflux disease treated with proton pump inhibitors.

The patient underwent a partial AVSD repair with primum atrial septal defect closure using autologous pericardium, cleft closure of the left AV valve and two partial left AV valve commissurotomies.

Intraoperatively, standard monitors were applied, including a five-lead ECG, non-invasive blood pressure and pulse oximeter. An arterial line and a 16G IV line were inserted. The patient was then preoxygenated and induced with midazolam, fentanyl, propofol and rocuronium bromide. Anaesthesia was maintained with sevoflurane, with ranging intraoperative minimum alveolar concentration (MAC) levels between 0.7 and 1.0. Entropy, in combination with the patient's clinical appearance, was used as a guide for sleep depth. After the placement of a Cordis introduction sheath (8.5 Fr., Arrow International, Reading, PA, USA) into the right internal jugular vein, a pulmonary artery catheter (7 Fr. 110 cm, Edwards Lifescience, Irvine CA, USA) was inserted through the sheath. The balloon was inflated with the standard 1.5 cc of air and the catheter was intro-

Należy cytować wersję: Starzyk L, Yao E, Roche-Nagel G, Wasowicz M: Snaring swans: intraoperative knotting of pulmonary artery catheters. *Anaesthesiol Intensive Ther* 2016; 48: 66–70. doi: 10.5603/AIT.2016.0013.

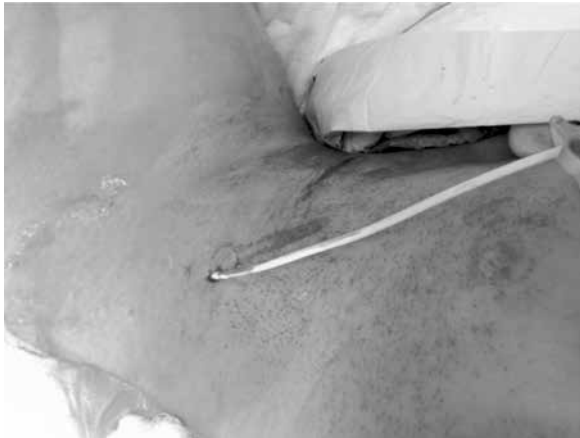

Figure 1. Patient's head on the right side: Cordis sheath at this stage removed, knotted PAC stuck at 10 cm at skin level

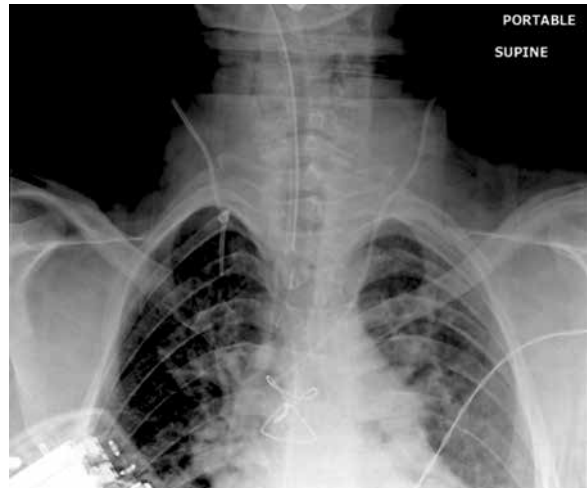


Figure 2. Chest X-Ray with the knotted PAC in situ

duced to a depth of approximately 50 cm. At this point, the pressure curve of the pulmonary artery was identified. The balloon was subsequently deflated and the catheter kept in position for hemodynamic measurements. During the repair of the congenital cardiac lesion, the catheter was withdrawn into the superior vena cava (SVC) until central venous pressure tracing was confirmed on the distal port of the catheter.

The cardiopulmonary bypass (CPB) course was uneventful, while CPB and total cross clamp time were 67 and 45 minutes, respectively. To obtain hemodynamic measurements after successful weaning from the bypass, the anaesthesia team attempted refloating the catheter.

After 4–5 attempts with maximal advancement of the catheter to a maximum depth of 45–50 cm, the PAC sleeve became contaminated with blood (valve failure) and it was decided to discontinue monitoring through the PAC. At this point, the operation was completed with a hemodynamically stable patient and without any other intraoperative complications.

Upon attempts to remove the catheter postoperatively before leaving the operating room, it became lodged at 16–18 cm (Fig. 1). As the catheter could be advanced into the RV again, the assumption was made that it had not been tied or sutured to any of the surgical repair sites. To confirm this thesis, a TEE exam was performed which could not identify the PAC in the cardiac chambers or adherent to the SVC. To have further visual confirmation of the position and the actual problem, a chest x-ray (CXR) (Fig. 2) was performed, showing the position of the catheter in the SVC/ internal jugular vein (IJV) with obvious knotting. In this situation, a vascular surgeon was consulted. As the diameter of the knot on the CXR was not much bigger than the original PAC diameter, the decision was made to try and remove the catheter without any surgical intervention. With firm and



Figure 3. Extraction technique with force and counter force

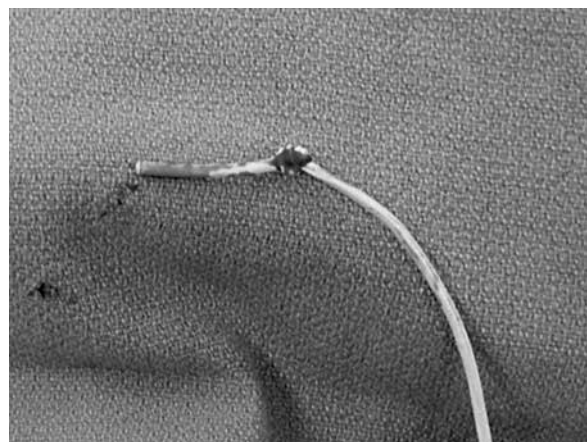


Figure 4. PAC after extraction

continuous pulling force and counter traction on the initial puncture site, the catheter was slowly removed (Fig. 2). A knot was indeed found at the distal portion of the extracted catheter about 8 cm from the end (Fig. 3, 4).

The further postoperative course remained uneventful and the patient was discharged on the 5th postoperative day.

Knotting of pulmonary artery catheters (PACs) occurs when catheters are repetitively advanced and/or when they are inserted at an excessive length [13]. Warming of the PAC by the blood causes the line to soften, further predisposing it to curl inside heart chambers. The pulmonary artery is typically reached with an insertion of 40–45 cm and the wedge position at 45–55 cm. Thus, if the pulmonary artery waveform is not observed at 50 cm, PAC looping is highly suspect [strongly suspected?? – Please Check] [3]. In cases of suspected knotting of a catheter, it is important use any form of imaging (Fluoroscopy, CXR and/or TEE). Moreover, it is essential to visualize the PAC in order to identify the position, distance and form of the knot before any action is taken. In cases of a loose knot, a guide wire may be introduced through the lumen of the PAC in order to untie the knot before it tightens [4].

In this case, the knot was likely formed during re-advancement of the catheter after it was retracted to clear the surgical field. It is hypothesized that the warm and pliable catheter looped around itself to form a knot while inside the right ventricle. Subsequent traction on the catheter from attempts at removal tightened the knot. Fortunately, the PAC knot diameter was small enough that, with steady traction on the proximal portion of the PAC and counter pressure on the site of PAC insertion on the right IJV, the knot was extracted without complications. Fluoroscopy and further surgical intervention were not required. Therefore, we concluded, that in upper SVC/IJV PAC entrapment, the catheter could be removed with a minimally invasive approach.

Coiling and knotting are rare but serious complications of pulmonary artery catheter insertions. Despite reported incidences of PAC knotting ranging from only 0.2% to 2.5% [5], PAC knotting accounts for more than two thirds of all incidences of intravascular catheter looping [6]. Pulmonary artery catheters are susceptible to intravascular knotting in both the intravascular space and around internal cardiac structures, with the most common sites being the right atrium, the right ventricle and the superior vena cava [5]. Procedural factors contributing to PAC coiling include blind introduction of the catheter, small diameter and inflexibility of the catheter, incomplete balloon inflation during introduction and multiple flotation attempts. Predisposing patient risk factors include dilated right heart chambers, tricuspid valve regurgitation, mechanical valves and abnormal venous anatomy [7]. Though the occurrence of PAC knotting is rare, interventions employed in the extraction of the knot, both surgical and non-surgical, frequently introduce a significant risk of additional complications and increase patients' mortality and morbidity [3]. Problems associated

with knotted PACs include infection (if left *in situ*), vessel or chamber rupture, thrombosis and arrhythmia. Table 1 summarizes the various types of interventions that have been employed to retrieve an intravascular knotted PAC. Major surgical intervention (sternotomy) poses the obvious risks of prolonged intubation, increased blood loss and increased cardiopulmonary bypass pump run time. As such, surgery is recommended only for complex PAC knots, such as large or multiple looped knots [5]. A less invasive surgical procedure for PAC knot removal is a venous cut-down, used in combination with a large bore introducer sheath or a dilator fitted over the top of the PAC. The sheath is used to reduce the knot size with traction, and as a guide for the knot during the course of its removal through the venous incision. Issues associated with this approach include the potential introduction of an air embolus or excessive bleeding via the venous incision [11]. Therefore, venous cut-down is recommended only for knots that are either too tight or too proximal [16]. Small, tightened knots can also be extracted via simple traction (as was done in this case) through the original insertion site. One concern with this method is that it introduces the risk for venous laceration, or catheter rupture causing a foreign body embolus [16, 18]. Furthermore, forced removal of a PAC knotted around an internal cardiac structure could potentially result in tricuspid valve and papillary muscle avulsion or chordae tendinae embolism. The literature suggests interventional radiological techniques as the preferred method of PAC knot removal. The knotted PAC can be removed heterotopically via the saphenous or femoral vein under fluoroscopic guidance [19, 20]. A dotter basket or loop snare catheter may also be employed to snare the knot and pull it out. However, even transfemoral removals of PAC knots pose a risk of venous laceration throughout its longer intravascular exit course [19], as well as concerns about contamination of the blood stream by the non-sterile proximal end of the catheter [16]. The alternative, minimally invasive management of a knotted PAC involves the threading of a core-guided wire through the lumen of the coiled PAC under fluoroscopy in an attempt to straighten the catheter and untie the knot. This method proves difficult if the knot has become too coiled or tightened [16].

In summary, we conclude that PAC knotting is a complication of PAC monitoring that can potentially lead to dangerous outcomes for the patient. To minimize the risk of PAC knotting, pressure waveforms should be continually monitored and repeated while excessive advancement of the catheter should be avoided. Failure to detect a pulmonary artery waveform at a maximum advancement of 55–60 cm suggests catheter coiling. Methods for extracting a formed PAC knot warrant further investigation. Based on current knowledge, it is advised to use imaging (CXR, fluoroscopy

Table 1. Summary of various interventions used to extract knotted pulmonary artery catheters

Reference	Presenting illness/procedure	Site of insertion	Method of PAC knot extraction
[8]	Bronchial carcinoma and concomitant chronic bronchitis and obstructive emphysema	Right basilic vein	Skin incision enlarged and PAC removed
[9]	Fracture dislocation of cervical spine with respiratory and renal failure	Right subclavian vein	Biliary stent catheter introduced over PAC and knot was removed together with the catheter sheath through the venipuncture site
[10]	Elective coronary revascularization	Right internal jugular vein	Knot was tightened against introducer and extracted together through skin incision, under fluoroscopic guidance
[11]	Abdominal aortic aneurysm dissection and repair	Right internal jugular vein	Transfemoral removal of knot under fluoroscopic guidance
[12]	Rheumatic heart disease with mitral stenosis and emergency MV replacement	Right internal jugular vein	Guide wire through PAC lumen with transfemoral biopsy forceps manipulation to untie knot. Extracted percutaneously.
[13]	CT-guided percutaneous drainage of splenic abscess, developed septic shock and respiratory failure	Right subclavian vein	Tracheostomy dilator inserted over catheter and PAC was removed along with the dilator
[14]	CABG	Right internal jugular vein	Re-sternotomy after traction attempts caused PA rupture
[6]	MV replacement and tricuspid annuloplasty	Left subclavian vein	Re-sternotomy; removed through SVC purse string incision
[15]	Cardiac surgery	Right internal jugular vein	Untied intraoperatively by surgeons
[16]	Total gastrectomy	Right internal jugular vein	Knot was attached to basket catheter and removed from the saphenous vein through an inguinal incision under fluoroscopic guidance
[17]	Liver resection for cirrhosis and liver cancer	Right internal jugular vein	Kinked introducer sheath and looped PAC extracted together percutaneously under fluoroscopy
[18]	Minimally invasive MV reconstruction for MV regurgitation	Right internal jugular vein	Knot was tightened against introducer sheath and extracted percutaneously
[4]	Worsening heart failure symptoms	Right internal jugular vein	Small skin cut-down and PAC removal under fluoroscopy
[19]	End-stage heart failure with respiratory insufficiency	Right subclavian vein	Transfemoral removal under fluoroscopic guidance
[20]	Cardiac arrest	Right internal jugular vein	Tightening of knot unravelled via femoral approach with the aid of a J-wire under fluoroscopy guidance

and or TEE) to assess the quality and complexity of the knot in order to choose the appropriate intervention. Although the traction with counter pressure method is the least invasive, it warrants good accessibility to the initial puncture site while conditions such as intracardiac knotting may preclude its use. If the knotted catheter can be retracted into a proximal position, it may be safe to remove it with gentle traction without further invasive methods. The potential complications of knot removal must be carefully understood and reviewed prior to proceeding with any intervention.

ACKNOWLEDGEMENTS

1. The authors declare no financial disclosure.
2. The authors declare no conflict of interest.

References:

3. American Society of Anesthesiologists Task Force on Pulmonary Artery Catheterization: Practice guidelines for pulmonary artery catheterization: an updated report by the American Society of Anesthesiologists

- Task Force on Pulmonary Artery Catheterization. *Anesthesiology* 2003; 99: 988–1014.
4. Evans DC, Doraiswamy AV, Prosciak MP et al.: Complications associated with pulmonary artery catheters: a comprehensive clinical review. *Scand J Surg* 2009; 98: 199–208.
5. Eshkevari L, Baker B: Occurrence and removal of a knotted pulmonary artery catheter: a case report. *AANA J* 2007; 75: 423–428.
6. Chen L, Huang P: Entrapment of a Swan-Ganz catheter. *J Chin Med Assoc* 2007; 70: 213–214.
7. Aggarwal N, Kupfer Y, Yoon T, Tessler S: Pulmonary artery catheter coiled in the main pulmonary artery trunk. *BMJ Case Rep* 2013. doi: 10.1136/bcr-2013-200049.
8. Georghiou GP: Knotting of a pulmonary artery catheter in the superior vena cava: surgical removal and a word of caution. *Heart* 2004; 90: e28–e28.
9. Chen C, Chen K, Taso S, Lin S, Lu K: Perforation of the right innominate vein by pulmonary artery catheter introducer sheath: a case report. *J Clin Anesth* 2009; 21: 206–208. doi: 10.1016/j.jclinane.2008.06.040.
10. Daum S, Schapira M: Intracardiac knot formation in a Swan-Ganz catheter. *Anesth Analg* 1973; 52: 862–863.
11. Dach JL, Galbut DL, LePage JR: The knotted Swan-Ganz catheter: new solution to a vexing problem. *Am J Roentgenol* 1981; 137: 1274–1245.
12. Tremblay N, Taillefer J, Hardy JF: Successful non-surgical extraction of a knotted pulmonary artery catheter trapped in the right ventricle. *Can J Anaesth* 1992; 39: 293–295.

13. *Ismail KM, Deckmyn TJ, E V, Vandermeersch E, Stockx L*: Nonsurgical extraction of intracardiac double-knotted pulmonary artery catheter. *J Clin Anesth* 1998; 10: 160–162.
14. *Mehta N, Lochab SS, Tempe DK, Trehan V, Nigam M*: Successful nonsurgical removal of a knotted and entrapped pulmonary artery catheter. *Cathet Cardiovasc Diagn* 1998; 43: 87–89.
15. *Akkerhuis MJO, Baul CG, Bauland CG, Voets AJ*: Percutaneous removal of a knotted pulmonary artery catheter using a tracheostomy dilator. *Crit Care (London, England)* 1999; 3: 131–133.
16. *Huang G, Wang H, Chen C, Ho S, Wong C*: Pulmonary artery rupture after attempted removal of a pulmonary artery catheter. *Anesth Analg* 2002; 95: 299–301.
17. *Matsuda T, Inoue S, Keiichi S, Furuya H*: Images in Anesthesia: accidental knot formation of a pulmonary artery catheter. *Can J Anaesth* 2004; 51: 1010.
18. *Lopes MC, de Cleve R, Zilberstein B, Gama-Rodrigues JJ*: Pulmonary artery catheter complications: report on a case of a knot accident and literature review. *Rev Hosp Clin Fac Med Sao Paulo* 2004; 59: 77–85.
19. *Bhatia P, Saied NN, Comunale ME*: Management of an unusual complication during placement of a pulmonary artery catheter. *Anesth Analg* 2004; 99: 669–671.
20. *Bossert T, Gummert JF, Bittner HB, Barten M, Walther T, Falk V, Mohr FW*: Swan-Ganz catheter induced severe complications in cardiac surgery: Right ventricular perforation, knotting, and rupture of a pulmonary artery. *J Card Surg* 2006; 21: 292–295.
21. *Papakostas JC, Papadopoulos LN, Arnaoutoglou HM, Karahaliou A, Matsagas MI*: Transfemoral removal of a knotted Swan-Ganz catheter. *Can J Surg* 2008; 51: E107–108.
22. *Rahim SA, Franke R, Mathew V*: Removal of a knotted Swan-Ganz catheter. *J Am Coll Cardiol* 2009; 53:e91. doi: 10.1016/j.jacc.2009.03.017.

Adres do korespondencji:

Lukasz Starzyk, MD
Staff Anaesthesiologist
Department of Anaesthesia and Pain Medicine
University Hospital Bern
3010 Bern, Switzerland
e-mail: Lukasz.Starzyk@insel.ch